

The Reliability of Digital Imaging in the Remote Assessment of Wounds

Defining a Standard

Robert X. Murphy, Jr, MD, MS,* Michael A. Bain, MD, MMS,* Thomas E. Wasser, PhD,†
Eric Wilson, MD,‡ and Walter J. Okunski, MD*

Context: Telemedicine has been used for remote management of many medical problems. Given the ever-expanding demands to provide increasing service with increasingly limited resources, quality care and practice efficiency can be enhanced by telemedicine.

Objective: This study was undertaken to explore the reliability of wound assessment using computer-transmitted digital imagery compared with a traditional bedside evaluation and also to assess its potential role in healthcare delivery.

Design/Setting/Patients: In the hospital setting, rounding vascular surgeons and a surgical resident evaluated the wounds on the service. A digital photograph was obtained with a 3.3 megapixel camera, and a wound-assessment tool was completed. A plastic surgery attending then reviewed the images at a later date and completed the same data tool.

Main Outcome Measures: Wounds were rated for eschar, exposed bone, cellulitis, purulence, swelling, granulation tissue, granulation color, and depth using a standardized data collection tool. κ statistics were computed for all variables, between raters.

Results: There were 2 phases of the study. In both phases, there was 100% agreement by the rounding physicians that the digital image was representative of the wound. Phase 1 agreement between evaluators was moderate to almost perfect, as demonstrated by κ values (range, 0.50–0.87). In phase 2, all variable κ values were rated as almost perfect, except the ability to evaluate depth of the wound to the millimeter, which was rated as substantial.

Conclusions: The ability to accurately evaluate a wound on the basis of a digital image is possible. However, it requires training of participants and is facilitated by use of an assessment tool. With these caveats, evaluation of wounds using digital images is equivalent to bedside examination. This technology can improve practice

efficiency, provide needed expertise at remote sites, and is an acceptable alternative method of wound assessment.

Key Words: wound assessment, computer-transmitted digital imagery, remote wound assessment, bedside evaluation, digital photography

(*Ann Plast Surg* 2006;56: 431–436)

Telemedicine has been used for remote management of many medical problems such as congestive heart failure and diabetes mellitus. “Nighthawk” technology allows radiologists at remote sites and in different time zones to evaluate radiologic studies. In surgery, telemedicine is used in trauma resuscitation at distant sites and for telerobotic procedures.^{1–7} The potential of telemedicine in wound care has been even recognized by Reuters Health News.⁸ Interestingly, the need for widespread investment in technology to provide “home and ambulatory monitoring of patients with chronic disease” is a priority second only to provision of hospital electronic medical records.⁹ Although intuitively valuable, this modality has yet to be accepted as an appropriate standard of care. This study was performed to explore the reliability of wound assessment at a distant site using computer-transmitted digital imagery compared with a traditional bedside evaluation in a multidisciplinary system. Specifically, clinical assessment of inpatient wounds provided by vascular surgeons and surgical resident were correlated with an evaluation performed by a blinded senior plastic surgeon studying digital images of those wounds. Further, we explore the potential implementation of this technology in a regional healthcare system.

METHODS

This study was conducted in an 800-bed academic community hospital. Study subjects were selected from the vascular surgery service. Criterion for inclusion was a wound of an extremity or torso in a hospitalized patient. In phase 1, 5 board-certified vascular surgeons, 2 board-certified plastic surgeons, and a postgraduate year (PGY)-3 plastic surgery resident participated. Phase 2 of the study was limited to 2 vascular attending surgeons, 1 plastic surgery attending, and a PGY-5 plastic surgery resident.

Received October 4, 2005, and accepted for publication, after revision, December 7, 2005.

From the *Division of Plastic and Reconstructive Surgery, †Community Health and Health Studies, and ‡Division of Vascular Surgery, Lehigh Valley Hospital, Allentown, PA.

Presented at American Association of Plastic Surgeons (AAPS), Scottsdale, AZ, May 8–11, 2005; and the Northeastern Society of Plastic Surgeons (NESPS) annual meeting, Naples, FL, January 19–23, 2005.

Reprints: Robert X. Murphy, Jr, MD, Lehigh Valley Hospital, Department of Surgery, Cedar Crest & I-78, P.O. Box 689, Allentown, PA 18105-1556. E-mail: sally.lutz@lvh.com.

Copyright © 2006 by Lippincott Williams & Wilkins

ISSN: 0148-7043/06/5604-0431

DOI: 10.1097/01.sap.0000202146.92893.6a

The camera used was a standard Sony S-75 3.3 mega pixel digital camera (Sony, Inc; Japan) with a 128-Mb smart media card. This camera was chosen because it is affordable, has digital zoom 5×, and a Carl Zeiss lens. Cameras of greater than 1.5 megapixels have shown to be sufficiently clear for medical photography.³ This particular media card allowed over 100 pictures to be taken at the given camera settings.

The guidelines of Galdino et al¹⁰ were followed. All images were taken using the macro function of the camera with 1 megabyte JPEG settings on fine resolution (the highest available for the camera). Matrix metering (camera default) and automatic white balance (camera default) were chosen. A light blue background was used for contrast: a sterile towel, plastic chuck, or diaper, depending upon availability. Automatic low flash was employed, given standard hospital room lighting. Photographs were taken an average of 18 to 24 inches from the patient. A disposable paper ruler was included in the picture to place the date and medical record number of the patient in the picture.

Informed consent was obtained from each patient to allow pictures of their wounds to be included in the study. Each patient underwent a visual assessment by the vascular attending surgeon and the plastic surgery resident. In both phases of the study, the assessment was followed by independent completion of the wound survey questionnaire rating eschar, exposed bone, cellulitis, purulence, swelling, granulation, color, and depth (Fig. 1). In phase 2, the data sheets were modified to remove pitting edema and substitute “swelling” in its stead. The digital photograph, taken by the resident, was shown to the attending vascular surgeon. The attending surgeon then determined whether the digital image was comparable to the physical examination.

All pictures in both phases of the study were reviewed at a remote location in blinded fashion by the senior attending plastic surgeon, who never personally examined any patient. Pictures were reviewed on a PC-compatible computer with a flat 17-inch Sony screen, which have been found to be acceptable to view wound pictures.¹¹ Reviewers were allowed to use the zoom capability of the Windows Picture Viewer (Microsoft, Inc.), and the wound evaluation tool was completed.

In phase 1, 2 pictures of each wound (n = 61) were taken in 31 patients. Only moderate to almost perfect inter-rater correlation was observed in phase 1. Phase 2 of the study was undertaken and modified to improve our results to a range which the authors considered a more appropriate threshold for adequate reproducible wound evaluation. Participants were limited to 2 vascular surgeons, 1 plastic surgeon, and the resident. In phase 2, 1 picture was taken of each wound (n = 56) in 37 patients. There was pre-study instruction as to the correct use of the wound evaluation data tool and strict adherence to the requirement that the vascular surgeon and the resident complete data sheets at the time of examination.

Data Analysis

Quantification of the variables assessed from the photographs were coded dichotomously (yes/no) for eschar, exposed bone, cellulitis, purulence, and swelling. Ordinal coding was used for granulation into percent intervals (0–25, 26–50, 51–75, and 76–100), color (pale, pink, and red/bleeding), and depth (1–2 mm, 3–4 mm, and 5 mm or more). κ statistics measuring agreement between the resident, vascular attending, and plastic attending were then calculated using methods defined by Siegel and Castellan.¹²

RESULTS

In all wound evaluations, there was absolute agreement by the attending and resident surgeons that the digital images were valid representations of the wounds (Fig. 2).

Phase 1 κ statistics can be found in Table 1; phase 2 κ statistics can be found in Table 2. The numeric value of the κ statistic was interpreted using the scale of agreement defined by Landis and Koch,¹³ where κ values less than 0.00 indicate poor agreement, and values increasing from 0.00 to 1.00 in 0.20 increments are assessed as slight, fair, moderate, substantial, and almost perfect, respectively.

Phase 1 data indicated lower levels of agreement than would be universally acceptable. Only 1 κ value was in the almost perfect range (eschar $\kappa = 0.871$). All other κ statistics were in the substantial range of 0.60 to 0.80, except for purulence and granulation, which showed moderate levels of agreement (0.502 and 0.561, respectively).

All phase 2 results were in the almost perfect range from 0.80 to 1.00. Only “depth” was less than 0.80 and was rated as substantial agreement (0.6994). Examination of the 95% confidence intervals indicates the population agreement for the “granulation” variable could be in the substantial range because the lower bound of the interval is less than

Patient Name: _____ MR#: _____

Date of Surgery: _____

	YES	NO			
Eschar	<input type="checkbox"/>	<input type="checkbox"/>			
Exposed bone	<input type="checkbox"/>	<input type="checkbox"/>			
Cellulitis	<input type="checkbox"/>	<input type="checkbox"/>			
Purulence	<input type="checkbox"/>	<input type="checkbox"/>			

	None	Non-pitting	+	++	NA
*Swelling	<input type="checkbox"/>	<input type="checkbox"/>	<input type="checkbox"/>	<input type="checkbox"/>	<input type="checkbox"/>

	0-25%	26-50%	51-75%	76-100%	NA
Granulation	<input type="checkbox"/>	<input type="checkbox"/>	<input type="checkbox"/>	<input type="checkbox"/>	<input type="checkbox"/>

	Pale	Pink	Red & Bleeding	NA
Color	<input type="checkbox"/>	<input type="checkbox"/>	<input type="checkbox"/>	<input type="checkbox"/>
	>3 mm	3 mm	2 mm	1 mm
Depth	<input type="checkbox"/>	<input type="checkbox"/>	<input type="checkbox"/>	<input type="checkbox"/>

Is digital image representative of patient's condition? YES NO

Attending Physician: _____

Date: _____

*Pitting is defined as a depression in response to maximum thumb pressure applied for 10 seconds not over bony prominence within 1 cm of wound margin.

+ If it then resolves <10 sec

++ If it persists >10 sec

NA Cannot perform

FIGURE 1. Wound assessment data sheet.

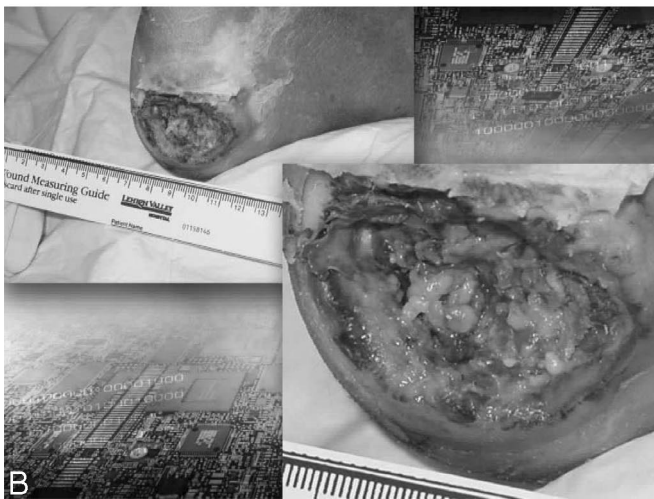
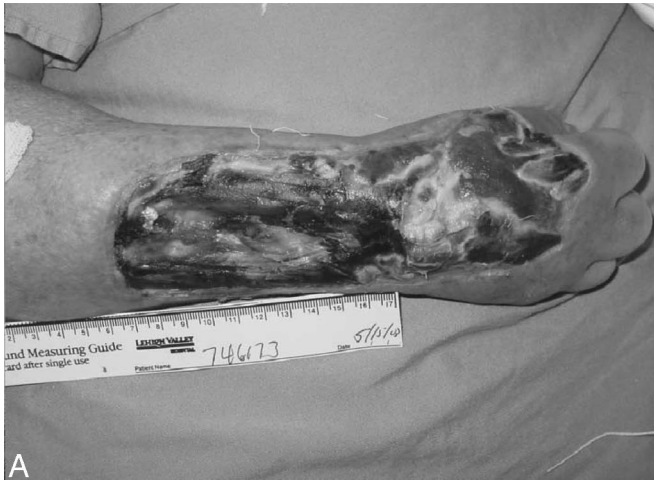

FIGURE 2. A, Representative wound of the forearm evaluated on rounds. Note exposed bone, tendon, eschar, granulation. B, Representative wound of heel evaluated on rounds. Note ability to magnify image with Picture Viewer and standard image.

TABLE 1. Phase 1 κ Results and Interpretation (n = 61 Wounds)*

Variable	κ	95% Confidence Interval of κ	Landis Agreement Level
Eschar	0.871	0.787–0.955	Almost perfect
Exposed bone	0.782	0.678–0.886	Substantial
Cellulitis	0.657	0.538–0.776	Substantial
Purulence	0.502	0.377–0.627	Moderate
Swelling	0.649	0.529–0.769	Substantial
Granulation	0.561	0.436–0.686	Moderate
Granulation color	0.667	0.549–0.785	Substantial
Depth	0.661	0.542–0.800	Substantial

*Digital image representative of patient’s condition? Yes = 100%.

0.80. Also, the population agreement for “depth” could be in the moderate range because the lower bound of the interval is below 0.60.

TABLE 2. Phase 2 κ Results and Interpretation (n = 56 Wounds)*

Variable	κ	95% Confidence Interval of κ	Landis Agreement Level
Eschar	0.9881	0.9597–1.0000	Almost perfect
Exposed bone	0.9762	0.9363–1.0000	Almost perfect
Cellulitis	0.9881	0.9597–1.0000	Almost perfect
Purulence	0.9881	0.9597–1.0000	Almost perfect
Swelling	0.9405	0.8785–1.0000	Almost perfect
Granulation	0.8452	0.7505–0.9399	Almost perfect
Granulation color	0.9167	0.8443–0.9891	Almost perfect
Depth	0.6994	0.5793–0.8195	Substantial

*Digital image representative of patient’s condition? Yes = 100%.

DISCUSSION

Telemedicine is currently used in regional centers throughout Europe and is gaining increasing acceptance in the United States, despite potential security issues.¹⁴ In surgery, it has been particularly valuable in facilitating trauma treatment and resuscitation from remote sites.^{15,16}

Photographs have been used in medicine for illustration and documentation purposes for over 100 years. The 35-mm slide has long been the gold standard of medical photography. The typical 35-mm Kodachrome slide contains approximately 4096 by 2736 pixels per frame. In 1974, Zarem¹⁷ described guidelines for plastic surgery photography. Roth et al^{11,18} determined that digital photography was equivalent to the previously accepted 35 mm slide photography. Galdino et al¹⁰ defined standards for digital photography in 2001. Due to the abilities of digital camera sensors,¹⁹ we feel that the improved definition produced by 3 megapixels provides sufficient technological advantage without incurring undue cost.

The ease of transmission of digital images offers this technology as a potential tool for accurate assessment of an image at a distance in a timely fashion. Our study concurred with that of Kim et al²⁰ in that digital imaging was an accurate modality for wound evaluation when compared with bedside examination. Specifically, the authors suggested that agreement of telemedicine is not always high but may not be significantly less than actual interphysician agreement at the bedside. The sine qua non of this process is the ability of independent observers to both reliably transmit and interpret information.

Phase 1 of our study revealed reasonable agreement between assessors. Standards for reliability requirements vary, depending upon the trait being observed. Thompson²¹ suggests that reliability in the estimates in the range of 0.5 to 0.6 can be considered acceptable. Nunnally and Bernstein²² argue that estimates at or above 0.70 will suffice.

Our κ statistics were found to be in the range of those reported by other investigators, consistent with the positions of Thompson²¹ and Nunnally and Bernstein.²² However, it was our contention that these levels remained below those which would be acceptable in an optimal physician-patient relationship to render appropriate medical care; therefore, values at or above 0.80 or 0.90 in the almost-perfect agreement range would be required. In debriefing the participants in this

Identification Information Patient Number: Wound Number: Location: Lower Leg (), Right, Medial Type of Wound: Wound Acquired:		Wound Status: Clinician: Attending Physician: Assessment Date: Treatment Duration:	
Wound Measurements PHOTO	Length (mm): Width (mm): Depth (mm): Hypergranulated: Area (mm ²): Volume (mm ³):		Tunneling or Undermining: Tunneling position (o'clock): Maximum distance (mm): Sinus tract: Sinus tract position (o'clock): Maximum distance (mm):
Wound Details Stage: Exudate Amount: Exudate Type: S/S of Infection: Pulse: Odor: Pain: Wound Margin: Non-compliance: Wound visits Diet Off-loading/Protection Medication Dressing changes Limb elevation Exercise Compression Other		Debridement Level:	
Peripheral Skin Appearance Edema: Induration: Brawny Induration: Cellulitis: Rubor: Temperature:		Texture: Maceration: Callus: Friable: Rash: Dry/Scaly: Moist: Shiny: Colors Present:	
Wound Base Wound Base Descriptions Adherent Yellow Slough: Moist Yellow Slough: Dry Black Eschar: Moist Black Eschar: Granulation: Color:	% % % % %	Exposed Structure Exposed Tendon Exposed Ligament Exposed Muscle Exposed Joint Exposed Bone	
Assessment Notes			
Patient Name: Wound #: Lower Leg (), Right, Medial		Patient #: Date: / /	
Signature(s) and Date(s): _____			

FIGURE 3. Wound assessment details.

phase of the study, it was felt that reproducibility could be improved with the maturation of surgical resident over the study course,¹¹ the requirement that all data tools be completed at the time of actual examination (rather than at the end of rounds or day), and by providing strict definition of terms used in the data tool (eg, if bone was present at base of wound but completely covered by granulation tissue, it should not fall into category of “exposed bone” since technically it was not visible).

Given the ever-expanding demands to provide services with limited resources, quality care and practice efficiency might be enhanced by telemedicine. As early as 1988, Wirthlin et al²³ explored the capability of telemedicine and digital photography for remote wound diagnosis using an early-generation digital camera (Kodak DC 50, 756 × 504 pixels). When a brief history was provided to the remote surgeons, κ ranged from 0.12 for erythema to 0.70 for ischemia. In 2004, Jones et al²⁴ demonstrated that the depth of burn wounds could be diagnosed with reasonable consistency when the

same evaluator compared his bedside examination to his interpretation of digital images at a later time (κ scores of 0.53–0.60). Similarly, Braun and his dermatology colleagues²⁵ evaluated leg ulcers using mobile telephones with photographic capabilities (Nokia 7650, 640 × 480 pixels). They, too, obtained good agreement, κ ranging from 0.49 to 0.94, with a mean of 0.75.

In a 2003 pilot study involving 17 patients and 20 wounds, Halstead et al²⁶ suggested that teleassessments of wounds might suffice in determining the need to refer a patient to a specialist or for making treatment decisions. “Teleconsultation” using mobile camera phones has recently been shown to be both feasible and valuable in the diagnosis and triage of digital soft tissue injuries in Taiwan.²⁷

In this study, we were able to show excellent interrater agreement (κ ranges from 0.6994 to 0.9881, with a mean of 0.9178), despite the involvement of different specialists and surgeons of different levels of training. This was accom-

plished by providing appropriate training of participants and utilizing technology which provides enhanced resolution when compared with previous studies. This level of correlation allows for a high degree of confidence in the use of this technology, which is so important, given our need to provide excellent patient care, as well as those imposed by the current demands of the medicolegal environment.

Digital technology allows the practitioner to be the recipient of visual data without the inefficiencies of repeated office visits or travel to multiple sites. Patients may be seen and a wound examined via a photograph accompanied by a straightforward assessment tool or interactive telephone communication. As recently determined by Galdino et al¹⁰ and supported by this study, if a JPEG, 1-megabyte file size is used, the photograph is equal to physical examination for the purposes of wound assessment. However, some wounds are very difficult to assess based on purely visual cues. For example, a stage IV pressure ulcer might have only a small skin wound but might have significant undermining and deep necrosis. Although the visual information allows a remote examiner to appreciate the qualities of the wound, the use of a data tool facilitates both the remote examiner's appreciation of these specific characteristics as well as longitudinal evaluation of wound progress and outcome data (Fig. 3). This practice is currently being used in our wound centers; specifically, measurements and characteristics of the wound are documented at each visit.

Interestingly, the newest generation of personal desktop assistants (PDAs) allows direct data entry and also has a 3-megapixel camera from which patient data may be downloaded into a central database. In our healthcare network, we currently employ telemedicine in multiple venues. In the outpatient setting, it is used to assess conditions such as congestive heart failure and fetal distress. Further, we have recently established a remote intensive care unit utilizing MetaVision to oversee critically ill patients in 2 geographically distinct locations. Finally, we have begun to link remote wound care programs at distant hospitals to our center to augment the expertise that they can provide. We have found digital imaging of wounds to be an important component of a complete telemedicine program.

This study by no means suggests that digital technology should undermine the traditional patient-physician relationship. However, with an aging population with significant comorbidities that will place increasing demands on our healthcare system to provide high-quality care in an outpatient setting, new processes and technologies must be employed due to limitations in resources, including the nursing and physician workforce. Since we now have the capability to obtain high-quality digital images and relay them in real time, digital imagery is one such tool that can help meet this need.

Our study corroborates that digital images of wounds accurately reflect a bedside evaluation and demonstrates that a remote evaluator can precisely assess a wound based on these images and a data tool when all providers are appropriately trained. This is significant because it will allow practitioners of various backgrounds and training to be involved in various aspects of a wound program while provid-

ing very high levels of reproducibility and quality. Ultimately, as this technology gains acceptance, it could be used as a regional resource in underserved areas.

Unfortunately, one of the major challenges to telemedicine is the lack of universal recognition and support by the federal government and insurance carriers; the implications of this on the more universal implementation of telemedicine are unclear at this time.

CONCLUSION

Given the advances in technology that have occurred during the last 10 years, such as increased computer speed, increased data transfer rates, and affordability of cameras and computers, there are fewer impediments to the use of digital images for medical practice. With the ever-increasing stresses placed on the medical system to provide quality and timely care, new technologies must be implemented. This study demonstrated that the remote assessment of wounds using digital imagery is equivalent to actual physical examination of routine wounds. Therefore, in a multidisciplinary system which standardizes wound evaluation with provider training and the use of a data tool, telemedicine can be a valuable modality in wound assessment and practice efficiency. These data support the concept that it can also be considered an equivalent method of wound evaluation and can be a useful modality in providing specialized care to areas of limited resources.

REFERENCES

1. Jones SM, Milroy C, Pickford MA. Telemedicine in acute plastic surgical trauma and burns. *Ann R Coll Surg Engl*. 2004;86:239–242.
2. Pap SA, Lach E, Upton J. Telemedicine in plastic surgery: e-consult the attending surgeon. *Plast Reconstr Surg*. 2002;110:452–456.
3. Jin AJ, Martin D, Maberley D, et al. Evaluation of a mobile diabetes care telemedicine clinic serving Aboriginal communities in Northern British Columbia, Canada. *Int J Circumpolar Health*. 2004;63(suppl 2):124–128.
4. Scalvini S, Zanelli E, Volterrani M, et al. A pilot study of nurse-led, home-based telecardiology for patients with chronic heart failure. *J Telemed Telecare*. 2004;10:113–117.
5. Haley L. Telemedicine treats trauma in rural B.C. Available at: <http://www.medicalpost.com/mpcontent/article.jsp?content=/content/EXTRACT/RAWART/3811/53A.html>. Accessed April 20, 2005.
6. Jerant AF, Nesbitt TS. Heart failure disease management incorporating telemedicine: a critical review. *JCOM*. 2005;4:207–217.
7. Anvari M. Remote telepresence surgery. *Laparosc Today*. 2005;4:5–7.
8. Reuters Health News. Picture phones may make a doctor's house calls. *Reuters Health News*. February 22, 2005.
9. Coye MJ. *The Technology Imperative: Futurescan: Healthcare Trends and Implications 2005–2010*. Chicago, IL: Society for Healthcare Strategy and Market Development of the American Hospital Association; 2005:16–22.
10. Galdino GM, Vogel JE, Vander Kolk CA. Standardizing digital photography: it's not all in the eye of the beholder. *Plast Reconstr Surg*. 2001;108:1334–1344.
11. Roth AC, Reid JC, Puckett CL, et al. Digital images in the diagnosis of wound healing problems. *Plast Reconstr Surg*. 1999;103:483–486.
12. Siegel S, Castellan N. *Nonparametric Statistics for the Behavioral Sciences*. 2nd ed. New York, NY: McGraw-Hill Book Company; 1988.
13. Landis JR, Koch CG. The measurement of observer agreement for categorical data. *Biometrics*. 1977;33:159–174.
14. Ratner D, Thomas C, Bickers D. The uses of digital photography in dermatology. *J Am Acad Derm*. 1999;41:749–756.
15. Ong AW, Gonzalez P, Ting M, et al. An easy and reproducible method of assessing healing of the open abdomen by digital image analysis. *Plast Reconstr Surg*. 2001;108:1704–1706.
16. Neuse WHG, Neumann NJ, Lehmann P, et al. The history of photography in dermatology. *Arch Dermatol*. 1996;132:1492–1498.

17. Zarem HA. Standards of photography. *Plast Reconstr Surg.* 1984;74:137–146.
18. Roth AC, Reid JC, Concannon M. Diagnostic quality of low resolution images for tele-woundcare. *Proc/AMIA Symp.* 1998;917–920.
19. McNamara MJ. Against the grain. *Popular Photography Imaging.* 2005;69:34–37.
20. Kim HM, Lowery JC, Hamill JB, et al. Accuracy of a web-based system for monitoring chronic wounds. *Telemed J E Health.* 2003;9:129–140.
21. Thompson B. *Score Reliability: Contemporary Thinking on Reliability Issues.* Thousand Oaks, CA: Sage Publications; 2003.
22. Nunnally JC, Bernstein I. *Psychometric Theory.* 2nd ed. New York, NY: McGraw Hill; 1978.
23. Wirthlin DJ, Buradagunta S, Edwards RA, et al. Telemedicine in vascular surgery: feasibility of digital imaging for remote management of wounds. *J Vasc Surg.* 1998;27:1089–1099.
24. Jones OC, Wilson DI, Andrews S. The reliability of digital images when used to assess burn wounds. *J Telemed Telecare.* 2004;10:185.
25. Braun RP, Vecchietti JL, Thomas L, et al. Telemedical wound care using a new generation of mobile telephones. *Arch Dermatol.* 2005;141:254–258.
26. Halstead LS, Dang T, Elrod M, et al. Teleassessment compared with live assessment of pressure ulcers in a wound clinic: a pilot study. *Adv Skin Wound Care.* 2003;16:91–96.
27. Hsieh C-H, Tsai H-H, Yin J-W, et al. Teleconsultation with the mobile camera-phone in digital soft-tissue injury: a feasibility study. *Plast Reconstr Surg.* 2004;114:1776–1782.